



## International Journal of Case Reports in Orthopaedics

E-ISSN: 2707-8353

P-ISSN: 2707-8345

IJCRO 2022; 6(2): 16-19

Received: 11-02-2022

Accepted: 15-03-2022

**Dr. Tathagata Bose**

2nd Year, DNB PGT, Medica  
Institute of Orthopedic  
Sciences, Medica  
Superspecialty Hospital,  
Kolkata, West Bengal, India

**Dr. Anirban Chatterjee**

Senior Consultant, Medica  
Institute of Orthopedic  
Sciences, Medica  
Superspecialty Hospital,  
Kolkata, West Bengal, India

**Dr. Vikash Kapoor**

Director and HOD, Medica  
Institute of Orthopedic  
Science, Medica Superspecialty  
Hospital, Kolkata, West  
Bengal, India

**Dr. Ejaz Bari**

Senior Consultant and HOD,  
Department of Radiodiagnosis,  
Medica Superspecialty  
Hospital, Kolkata, West  
Bengal, India

**Corresponding Author:**

**Dr. Tathagata Bose**

2nd Year, DNB PGT, Medica  
Institute of Orthopedic  
Sciences, Medica  
Superspecialty Hospital,  
Kolkata, West Bengal, India

## Primary benign fibrous histiocytoma of bone: A case report

**Dr. Tathagata Bose, Dr. Anirban Chatterjee, Dr. Vikash Kapoor and Dr. Ejaz Bari**

DOI: <https://doi.org/10.33545/orthor.2022.v6.i2a.360>

### Abstract

Benign Fibrous Histiocytoma is such a rare tumor that only a few cases have been reported in the literature. A patient with an apparently benign lesion of the distal femur presented at our Outpatient Department. Pain was the chief complaint. There were histological features of Non-ossifying Fibroma in the lesion. Because of its unusual radiological appearance and atypical clinical course, the lesion was diagnosed as Fibrous Histiocytoma. In this case report, we discuss about such a rare case. This 55 years old male patient with history of chronic kidney Disease came with complaints of pain over medial aspect of left knee, initially was managed elsewhere with conservative management. Referred to Orthopaedic surgery department for further management. After all necessary investigations, was planned for Incisional Biopsy. After the biopsy report, was planned for definitive management with Extended Curettage and Prophylactic fixation.

**Keywords:** Benign fibrous histiocytoma, giant cells

### Introduction

Benign fibrous histiocytoma (BFH) of bone is extremely rare <sup>[1]</sup> with reported incidence of 1% of surgically managed benign bone tumors <sup>[2]</sup>. The histological features are of a spindle cell neoplasm with a storiform pattern, giant cells and foam cells which is indistinguishable from non-ossifying fibroma and metaphyseal fibrous cortical defect <sup>[3]</sup>. They are all benign self-limiting and self-healing unless accompanied by pathological fracture.

Patients with BFH are usually more than 20 years of age with a slight female preponderance. These lesions in most cases (65%) are accompanied by pain which may be present for days upto several years <sup>[2, 4]</sup>. Occasionally patients present with a pathological fracture <sup>[5]</sup>.

BFH is a mesenchymal tumor that is believed to originate from fibroblasts and histiocytes. Nonetheless, its lineage remains vague and its etiology unknown <sup>[9, 10]</sup>.

The giant cells in BFH tend to have fewer nuclei than those found in osteoclastoma or giant cell tumor (GCT).

Radiological findings are variable and non-diagnostic as osteolysis, trabeculation, bone sclerosis are seen which may resemble other benign bone tumors.

BFH is usually centred in the epiphysis or diaphysis.

We report a rare case of BFH that occurred at metaphysis of distal femur mimicking GCT in an elderly patient with chronic kidney disease.

The purpose of this article is to describe the clinical and microscopic appearance of BFH, and also focus on the treatment options best suited to treat BFH.

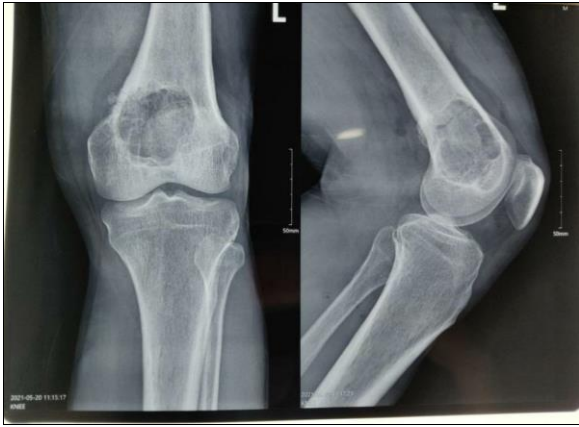### Case report

A 55 year old male, a known case of chronic kidney disease presented with complaints of swelling over medial aspect of left knee while walking since 4 months.

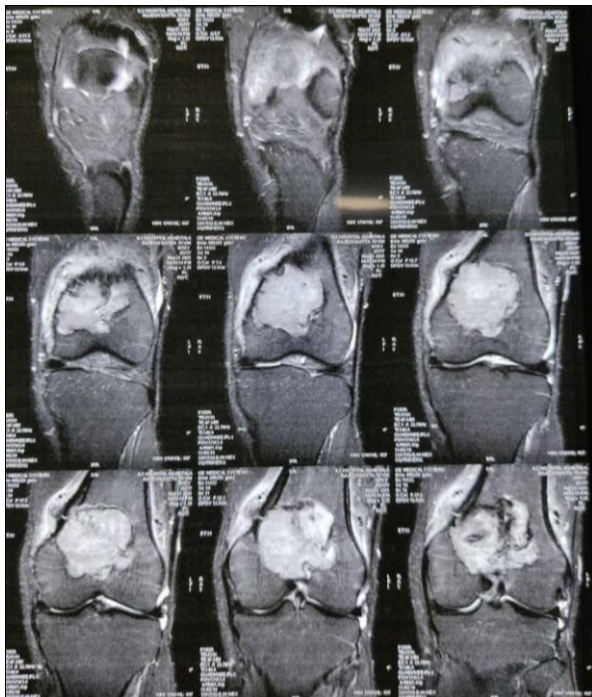
There was no history of trauma or injury preceding onset of symptoms. He had consulted local doctor and was managed conservatively with a knee brace and analgesics for pain relief. He was referred to orthopaedic surgeon for further treatment.

His general examination revealed no significant abnormal findings.

Local examination showed a swelling over medial aspect of left knee joint approximately measuring 4x3cm. It was hard in consistency, non-fluctuant and not attached to skin. Tenderness was present over medial aspect of left knee joint. Range of movement at the knee was terminally restricted and painful. Crepitus was felt while doing joint movements.



**Fig 1:** X-Ray showed a lytic, destructive, expansile lesion involving Right distal femur, eccentric in location with a sclerotic rim.

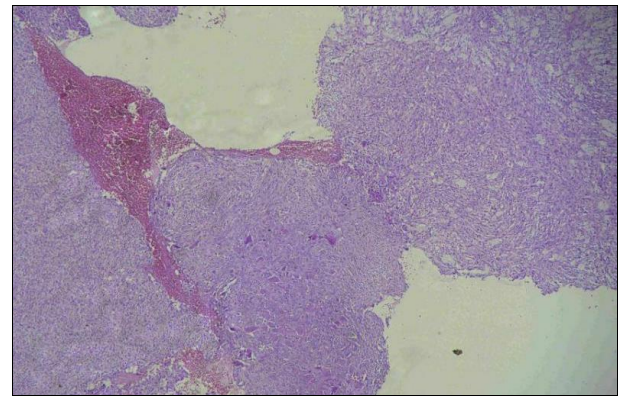


**Fig 2:** MRI showed a lobulated lytic lesion measuring 5.2 x 5.3 x 4.9 cm in metaphyseal region of femur. No calcification, haemorrhage, or air fluid level was seen. Narrow zone of transition. Cortical breach was noted in medial and inferior surface. Irregular periosteal thickening was present over the medial aspect. Soft tissue changes noted in medial aspect, extending to vastus medialis.

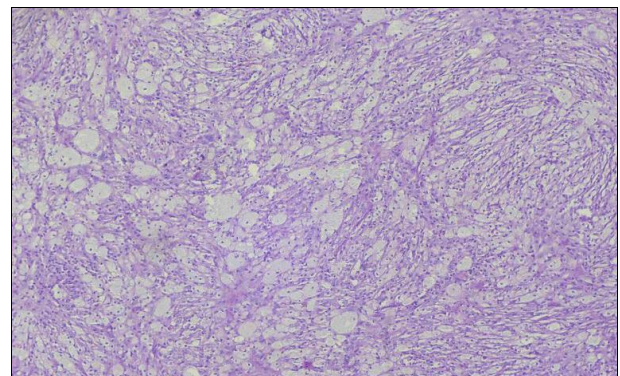
Radiological differential diagnosis were: Non ossifying fibroma, infection, Chondroblastoma, Fibrous dysplasia, GCT.

An incisional biopsy was taken from left distal femur under spinal anaesthesia and material obtained was sent for histopathological examination. Hematoxyline and Eosin stained sections showed spindle cells arranged in storiform pattern (Fig 3). The cells had bland nuclei with moderate to abundant cytoplasm and indistinct cell margins. Scattered foam cells (Fig 4), and osteoclast type giant cells were seen (Fig 5). No pleomorphism or atypical mitosis was found. A

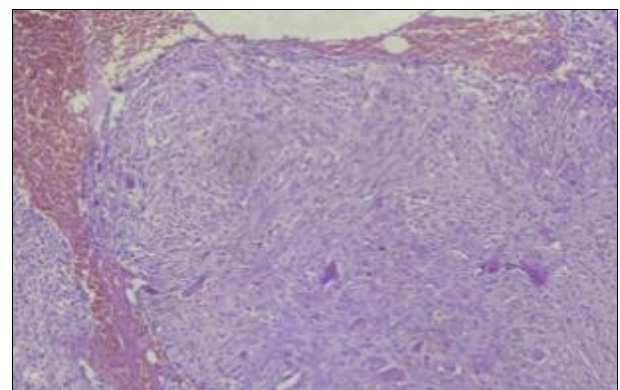
diagnosis of benign fibrohistiocytic tumor was made with possibilities of BFH, None ossifying Fibroma (NOF) and Fibroxanthoma.



**Fig 3:** Spindle cells in storiform pattern (40 X)

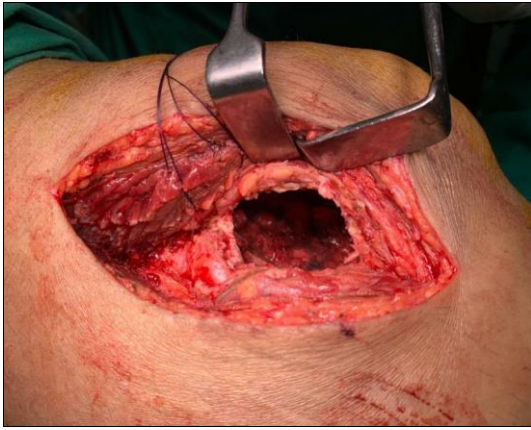

**Fig 4:** Foam cell aggregates (100 X)



**Fig 5:** Multinucleated giant cells in a background of spindle cells (100 X)

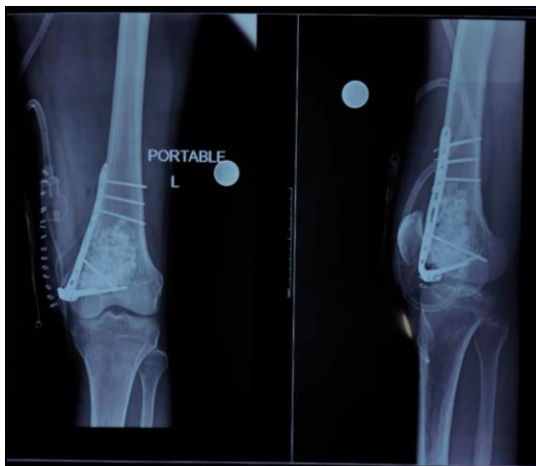After obtaining the incisional biopsy report, the patient was prepared for definitive management of the bone lesion. Treatment consisted of extended curettage of the lesion, (i.e. curetting out the lesion and extending the intralesional margin using a power burr) chemical cauterization of the cavity (*viz.* 5% Phenol, Absolute Alcohol, Hydrogen peroxide). The cavity was filled using autogenous iliac crest bone grafting and prophylactic internal fixation was done to prevent further pathological fracture and allow early mobilisation.



**Fig 6:** Intra operative picture showing a cortical window made in the distal femur and the cavity being curetted out, with the vastus medialis muscle reflected with stay sutures.



**Fig 7:** gross image of bone curettings



**Fig 8:** Immediate Post-operative X-ray

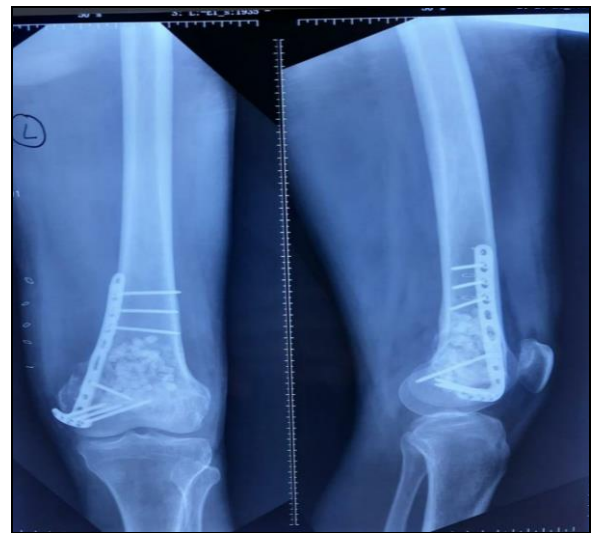**Histopathology**

**Gross examination:** greyish white tissue pieces together measuring 2 x 1.5 x 1 cm.

**Microscopy:** Section showed similar histological findings as in incisional biopsy with tissue fragments composed of loosely arranged proliferating polygonal to spindle mononuclear cells with reniform bland nuclei in storiform pattern with scattered lipid laden macrophages,

hemosiderophages and multinucleated osteoclastic giant cells. No abnormal mitotic figures, necrosis or frank cellular atypia seen. A final diagnosis of Benign Fibrous Histiocytoma of bone was made.

**Follow up:** Patient’s pain at the lesion site disappeared completely within 14 days after surgery. At the latest follow up (6 weeks), patient is comfortable, ambulating with assisted weight bearing using a walking aid. Radiographs do not reveal any sign of recurrence. Patient is being kept on regular follow up.



**Fig 9:** 3 Weeks Follow Up X-ray

**Discussion**

BFH is a tumor of unknown etiology that comprised of fibroblasts and histiocytes. The lineage of this tumor has not been fully explained even though it was first described by Dahlin in 1978 [10, 11, 12]. These tumors can be anatomically classified into cutaneous and deep forms, the latter form are rare (1%-2% of all BFHs) [11, 13].

BFH is a well-known tumor arising in soft tissues, but is a very rare bone tumor accounting for about 1% of all benign bone tumors [2]. Within the bone, it occurs commonly in spine, pelvis, facial bone or in tubular bones like distal femur and proximal tibia [7]. However there is a diagnostic challenge as it resembles no ossifying fibroma, or a metaphyseal fibrous defect microscopically. Histologically it is composed of spindle shaped fibroblasts arranged in storiform pattern with varying degree of multinucleated giant cells and foam cells [2]. Therefore it is suggested that BFH should not be distinguished from NOF based on histology alone but rather on clinical and radiological grounds. Clinically in BFH pain has to be considered as principle symptom and median age over 20 years is a considered factor that may differentiate BFH from NOF [3]. All these tumors (i.e BFH, NOF) have low recurrence rate [6].

Our case is a 55year old male who presented with symptom of pain in knee.

NOF always occur in children and adolescent less than 20 years and is considered as a development defect and usually has a self-limited process [2, 3]

Clinically NOF are usually asymptomatic except in case of pathological fracture and the lesion is often found incidentally on radiographs done for some other purpose whereas BFH frequently comes to notice due to pain at the lesion site [3]. NOF spontaneously regresses with skeletal maturity and in majority of cases no surgical treatment is needed. Haemorrhage or cystic change secondary to NOF appears to be extremely rare. Moreover, NOF is exclusively located in metaphysis of long bone. Therefore the clinical findings which is atypical for NOF could be clues to diagnosis of BFH.

Our case showed a radiological picture of expansile, lytic, destructive lesion in the metaphyseal region with sclerotic border eccentrically located in distal femur, with a clear margin and separation from the articular surface. The presentation of mass which was located in metaphysis of long bone extending to epiphysis led us to think of GCT, since radiologically GCT are encountered at Epiphysio-Metaphyseal junction. GCT is typically an aggressive, lytic lesion with poorly defined borders lacking surrounding rim of reactive sclerosis and sometimes with soft tissue extension and is usually juxta-articular while BFH commonly reveals this picture. GCT starts from metaphysis and lesion seldom extends to epiphysis before osseous maturity. It occurs almost when growth plate has closed and are therefore seen typically in early adulthood with 80% occurring between age 20 and 50 [8]. Most common presentation of GCT is pain, swelling and limitation of joint pain at the primary site. In BFH mass or swelling is not a frequent presenting symptom.

Microscopically BFH consists of a variable amount spindle shaped fibrohistiocytic cells forming storiform pattern, while GCT is composed of mononuclear cells intermixed with numerous uniformly distributed giant cells containing upto 50 nuclei or more and larger than those seen in other tumors. Larger areas of foam cells, lipid laden cells and abundant vacuolated cytoplasm. However, GCT contains numerous thin walled vascular channels predisposing areas of haemorrhage and presumably related to frequent coexistence of ABC found in 14% of cases. Moreover malignant transformation and lung metastasis of GCT are possible though rarely.

In contrast BFH does not undergo malignant change or metastasis although it can be locally aggressive and recur after curettage.

Treatment of BFH of bone consists of careful complete curettage and filling the defect with bone cement or bone graft [2, 4]. Prognosis is good although recurrence have been reported [2]. The treatment of choice for BFHs is wide resection of the tumor, resulting in an excellent prognosis and a low recurrence rate. We determined that wide excision proved to be adequate in preventing recurrence of the tumor, which confirms results previously reported in the literature. Wide excision is defined as excision of the mass with a confidence margin of 1–2 cm; however, consensus has not been reached on this issue [9, 10].

Adjuvant therapy is recommended to reduce the recurrence rate. Cryotherapy for benign aggressive tumors has excellent results reducing the recurrence rate to

approximately 3 to 5 %. En bloc excision may also be used if anatomic location allows for it and when multiple recurrences the lesion is unresectable.

In our patient, the diagnosis of BFH was based on clinical features his age at onset and the symptoms of pain and was later confirmed radiologically and histologically.

## References

1. Fibrohistiocytic and Fibrous Tumors Diagnostic Histopathology of Tumors 5<sup>th</sup> ed. Cristopher DM Fletcher, 12 Chapter 25, 2042.
2. Crohs JGM, Kainbuger F, Lang S, Kotz R. BFH of bone: report of 10 cases and review of literature. *Wein Klin Wochen chr*, 2002, 114-56-63.
3. Bertoni F, Calderoni P, Bacchini P, *et al.* *Am J Surg*, 9, 806-815.
4. Kyriakos IARC M. Benign fibrous histiocytoma of bone, 2006sep, 13. Available at [www.iarc.fr/en/publications/pdfs-online/pathogen/bb5chap13.pdf](http://www.iarc.fr/en/publications/pdfs-online/pathogen/bb5chap13.pdf)
5. Nagarekha Kulkarni Benign Fibrous Histiocytoma -A case report *IJCRI*. 2013;4(4):224-227.
6. Matsuno T. Benign fibrous histiocytoma involving the ends of long bone, *Skeletal Radiol*. 1990;19(8):561-6.
7. Zia SA, Raza SH. Benign fibrous histiocytoma of the rib. *J Pak Med Assoc*. 2001;51(4):162-3.
8. Clark BE, Xipell JM, Thomas DP. Benign fibrous histiocytoma of bone. *Am J Surg. Pathol*. 1985;9(11):806-815.
9. Chung Namkoong S, Sim JH, *et al.* Deep penetrating benign fibrous histio-cytoma of the foot associated with throbbing pain, *Ann. Dermatol*. 2011;23(Suppl2):S239-S242. <https://doi.org/10.5021/ad.2011.23.S2.S239>.
10. Arikanoğlu Z, Akbulut S, Basbug M, Meteroğlu F, Senol A, Mizrak B. Benign fibrous histiocytoma arising from the intercostal space, *Gen. Thorac. Cardiovasc. Surg*. 2011;59(11):763-766. <https://doi.org/10.1007/s11748-010-0760-2>.
11. Gleason BC, Fletcher CDM, Deep. Benign fibrous histiocytoma: clinicopathologic analysis of 69 cases of a rare tumor indicating occasional metastatic potential, *Am. J Surg. Pathol*. 2008;32(3):354-362. <https://doi.org/10.1097/PAS.0b013e31813c6b85>.
12. Kumar V, Abbas AK, Fausto N, Aster JC, Robbins Cotran. *Pathologic Basis of Disease, Professional Edition e-Book*, Elsevier Health Sciences, 2014.
13. Fletcher CD. Benign fibrous histiocytoma of subcutaneous and deep soft tissue: a clinicopathologic analysis of 21 cases, *Am. J Surg. Pathol*. 1990;14(9):801-809.